

Bilateral Invasive *Aspergillus flavus* Otitomycosis In a Diabetic Patient: A Case Report.

M. Smida¹, A. Mehrzi², H. Chouaieb¹, M. Chatti¹, M. Benseif¹, M. Abdelkefi¹, A. Fathallah¹.

1. Department of Parasitology Mycology, Farhat Hached University Hospital, Sousse, Tunisia

2. Department of ENT, Farhat Hached University Hospital, Sousse, Tunisia

INTRODUCTION

Otomycosis is a fungal infection of the external canal but can affect the middle ear. There has been an increase in fungal otitis cases in recent years. It can be the result of superinfection of chronic bacterial infection of the external canal or middle ear. Malignant external otitis is an aggressive and life-threatening condition. The most common fungus responsible for this infection is *Aspergillus spp.* Here, we aim to report a case of bilateral invasive otomycosis due to *Aspergillus flavus* in a diabetic patient.

CASE REPORT

A 56-year-old woman with a medical history of a long-standing type 2 diabetes mellitus treated with insulin, hypertension, kidney failure and hypothyroidism.

The patient presented with a severe bilateral otalgia with non-fetid otorrhea treated previously with a prolonged course of antibiotics without clinical improvement, she then was admitted to the ENT department. Physical exam revealed a well-calibrated and macerated external acoustic meatus with granulomas on the left side associated with profuse otorrhea, making difficult to see the tympanic membrane. Cranial nerves examination was normal. CT scans showed a bilateral necrotizing external otitis with signs of aggression. Initial laboratory findings were: white blood cells count: 11400/mm³; sedimentation rate: 91mm/hr; CRP: 45mg/L; creatinine clearance: 12 ml.min⁻¹.

Bacterial and fungal samples performed were negative for the first 3 days before starting a treatment adapted to the patient's renal condition, based on Tazocillin 4g/day and Ciprofloxacin 500mg/day in addition to daily local care for 14 days without any clinical improvement. A second cure based on Fortum 500 mg/day, Ciprofloxacin 500 mg/day and Vancomycin 250 mg/day for 36 days was administrated, again without any clinical or biological improvement.

Another series of bacterial and fungal samples and a polyp biopsy were carried out. Histological examination showed the presence of mycelial filaments and mycological culture grew *Aspergillus flavus* which confirmed the fungal origin of the infection. Identification of the *Aspergillus* species was based on morphology of colonies isolated on Sabouraud Chloramphenicol medium and on microscopic characteristics (Figures 1,2).

Voriconazole was then commenced, 400mgx2 for the first day followed by 200mgx2 per day for a total duration of 6 months.

The evolution was satisfactory biologically: white blood cells: 7800/mm³; sedimentation rate: 37 mm/hr; CRP: 17 mg/L, and clinically with the regression of all the signs and a remarkable response with a follow up of 6 months.

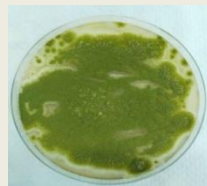


Figure 1 : showing yellowish green colonies of *Aspergillus flavus* on Sabouraud Chloramphenicol medium.

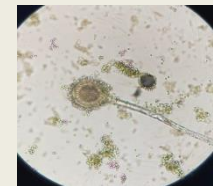


Figure 2 : Image showing conidial heads of *Aspergillus flavus* isolated.

DISCUSSION & CONCLUSION

Aspergillus species are ubiquitous filamentous fungi. They may cause a broad spectrum of disease in human, potentially invasive aspergillosis with a rapidly progressive and fatal course; especially in immunosuppressed patients [1,3]. The burden of aspergillosis is underestimated and has significantly increased in recent years. Invasive external otitis due to *Aspergillus spp.* remains uncommon but may have deleterious complications if not timely treated, [1, 2].

This observation highlights that *Aspergillus spp.* invasive otitis is a challenging condition. Diagnosis may be difficult and delayed. Biopsy may be needed and an invasive fungal etiology should be considered in a patient who does not respond to conventional antimicrobial therapy.

Furthermore, identification of fungus is often laborious in clinical laboratories with traditional phenotypic approaches. Molecular methods are scarce but necessary to identify species within sections. Voriconazole is currently recommended as the first-line treatment for invasive aspergillosis, as for our patient who responded to the fungal treatment. Surgical management is now mainly used for diagnosis and constitutes an adjunctive therapy [1-3].

There are several predisposing factors for malignant external fungal otitis including diabetes, steroids, instrumentation, dermatitis, and immunocompromising conditions. Early diagnosis and prompt treatment guided by culture results are the keys to improve outcome [1-3].

REFERENCES

- 1: E. Marchionni, P. Parize, A. Lefèvre, P. Vironneau, M. E. Bougnoux, *et al.* *Aspergillus spp.* invasive external otitis: favourable outcome with a medical approach. *Clin Microbiol Infect.* 2016;22(5):434–37.
- 2: J. Walton, C. Coulson. Fungal Malignant Otitis Externa with Facial Nerve Palsy: Tissue Biopsy Aids Diagnosis. *Otolaryngol Case Rep.* 2014; Article ID 192318.
- 3: J.L. Trevino Gonzalez , L.L. Reyes Suarez, J.E. Hernandez de Leon. Malignant otitis externa: An updated review. *Am J Otolaryngol.* 2021;42(2):102894.